

# Case Presentation

**Single ovarian cyst  
and effect of adjuvant use of  
PEMF Magnet Therapy using  
Anmol Pulsar V1  
(Kumar's Magnet)**

Conducted by:

**Dr Madhuri Patil B.A.M.S. M.D (Mumbai)  
Contact no. 9869161041,  
Email – drmadhurichaudhari@gmail.com  
Navi Mumbai**

# Case Summary

A single right sided ovarian cyst (suspected to be hemorrhagic in nature ) in an apparently healthy young woman is treated with Ayurvedic medicines and adjuvant use or concurrent use of PEMF (Pulsed Electro-Magnetic Frequency) Magnet therapy with Anmol Pulsar V1.

After 6 months of this treatment plan, USG of pelvic region was done. The single ovarian cyst was resolved along with clinically associated symptoms.

# Patient Description

An apparently healthy married 42 yrs. female with normal BMI of 22, presenting with pain during menstruation, pain during coitus, painful and burning sensation during urination, constipation, dry and itchy skin esp., on forearms, too much thirst and feelings of dryness all over body, acidity, indigestion.

# Complaints

Dysmenorrhea,

Dysuria,

Dyspareunia

Fatigue on exertion,

Pain in lower abdomen while walking. Burning sensation on and off on urination, urinary incontinence .

Extreme Intolerance to sweaty and hot conditions,

Dry and itchy skin

# Baseline Findings

Jivha- Saam, BMI within normal limits of 22

Agni- Madhyam

Prakruti- Vaat Pittaj

Pulse- Nadi- Pitta Vaataj, Ushna sparsh, Mandukvat gati,  
average 80pm, BP- Normal-110/80,

constipation, bloating in abdomen, eyes red

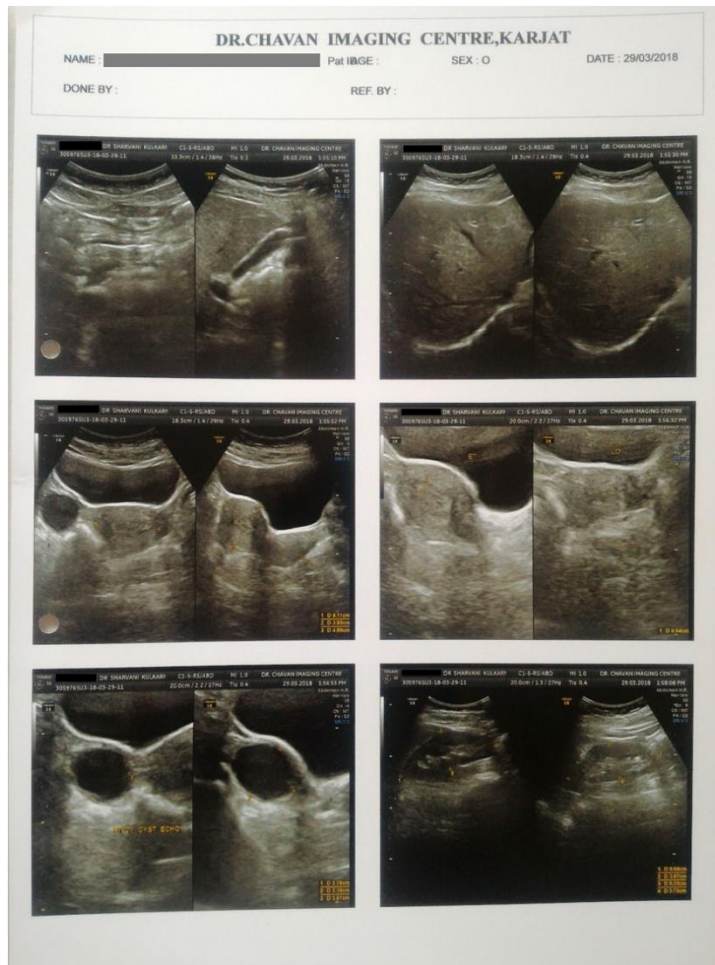Insomnia, tiredness, thirst too much, acidity post lunch,  
*Amlodgar*, Urination 3-4 times a day, scanty flow, frequent  
urination with pain and burning, no fever, no chills,  
with pain in lower abdomen,

Skin- dry, too much sweating, itching on forearms  
esp. heat intolerance

Menstruation -Irregular, Painful cramps, heavy bleeding 5  
days. On and off intense cramps in lower abdominal pain.

# Investigation Before Treatment

Before Treatment USG-A & P, on 29 03 2018



**DR. CHAVAN IMAGING CENTRE**  
DIGITAL X-RAY • SONOGRAPHY • COLOUR DOPPLER  
Bharat Arcade, Samaj Mandir Road, Khopoli, Dist. Raigad. Mobile : 9820521581 / 9223266180  
Mithila Complex, Amrai Road, Opp. Siddique Manzil, Karjat. Mobile : 9823534585 / 9689948585

MRS [REDACTED] 29.03.18  
DR SHARVANI KULKARNI  
**USG: ABDOMEN & PELVIS**

Fatty Liver, gall bladder, spleen, pancreas, both kidneys appear normal. No focal lesion.  
RK 10.1 x 3.3 cms LK 10.4 x 4.3 cms

Uterus is anteverted, measuring 8.1 x 4.9 x 3.9 cms.  
Normal in size shape echopattern. No focal lesion.  
Midline endometrial echo is normal.(5.4 mm)

**Adnexae/Ovaries:**  
Welldefined thin walled anechoic cystic lesion measuring 3.7 x 3.5 x 3.1 cms in size is seen in the right adnexal region. with internal echoes within.  
right ovary is not seen separately.

Left ovary normal .

No free fluid in cul de sac.

Urinary bladder:- is well distended  
No focal mural lesion or vesical calculus

**Impression :-** Uterus normal.  
Right ovarian cyst measuring 3.7 x 3.5 x 3.1 cms  
With internal echoes possibility of endometrioma / hemorrhagic cyst to be considered.

SUGGEST FOLLOW UP

*Dr. Alka Chavan*  
Dr. Alka Chavan  
M.B.B.S., D.M.R.D.  
Reg. No. 200422131

(Reg. No. RGD/KPR/177)  
(Reg. No. : RGD/KJT/275)

Dr. Gajanan Chavan  
M.B.B.S., D.M.R.D.  
Reg. No. 62147

# Diagnosis

Single ovarian cyst Measuring 3.7\*3.5\*3.1cms

and

Non-conclusive PCOS

# Treatment Plan

1. Dashmularishta 10ml
2. Saarivaadyasava 10 ml with lukewarm water
3. Punarnavashtak kashay , freshly prepared, 10ml, morning 20 minutes before PEMF therapy
4. Gandharva Haritaki 2tsp with Jaggery and Triphala ghrut 1 tsp, before dinner.
5. Shatdhaut Ghrut external application for skin.
6. Shatavari ghrut 2tsp with lukewarm water empty stomach.
7. Everyday PEMF Magnet therapy sessions of 20 minutes each in the morning with V1



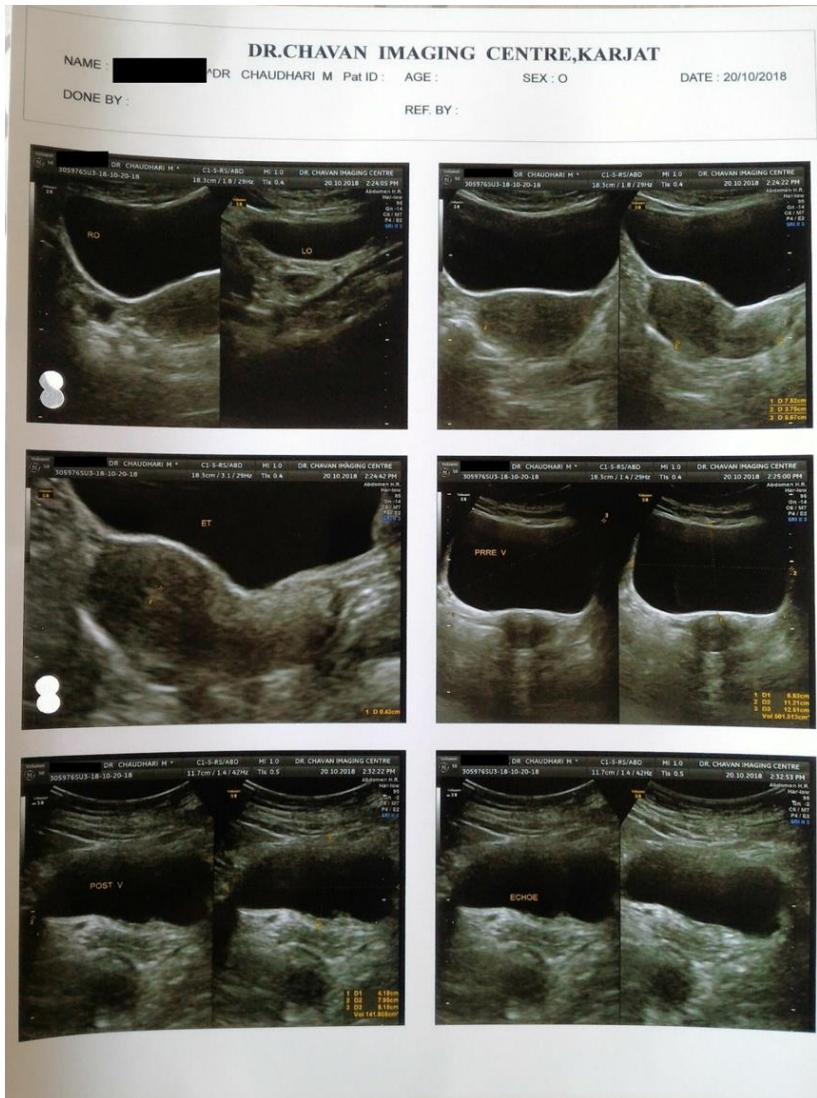
# Midpoint and Progress

PEMF Magnet therapy probe and magnets placements as shown In the picture. Post 2 months therapy, pain reduced in intensity. By 3<sup>rd</sup> month, regular and normal menstruation, no pain during menstruation, no pain during coitus or while walking, pain reduced during urination burning stopped by 5th month. No acidity. Or bloating sensation. Sleep improved.



# Investigation After Treatment

After Treatment USG A & P 20-10-2018



**DR. CHAVAN IMAGING CENTRE**

DIGITAL X-RAY • SONOGRAPHY • COLOUR DOPPLER

Bharat Arcade, Samaj Mandir Road, Khopoli, Dist. Raigad. Mobile : 9820521581 / 9223266180  
Mithila Complex, Amrai Road, Opp. Siddique Manzil, Karjat. Mobile : 9823534585 / 9689948585

MRS [REDACTED] 20.10.2018

DR. M CHAUDHARI

USG OF : PELVIS

Uterus is anteverted normal in shape and myometrial echoes.  
It measures 7.5 X 5.6 X 3.7 cms. No focal mass lesion  
Midline endometrial echo appears normal.(4mm)

Adnexae/Ovaries: Both ovaries are normal in  
size, shape with small follicles.  
No cystic or solid mass lesion.

No mass lesion in both adnexal region.

No free fluid in POD.


Urinary bladder:- well distended.  
Diffuse mild thickening & irregularity of bladder  
Wall, With internal echoes. No Vesical calculus.

Pre void 501 cc post void 141 cc

Impression : Diffusely thickened and irregular  
urinary bladder wall with internal  
echoes possibly due to CYSTITIS.

No ovarian cyst.

No obvious adnexal lesion.

  
**Dr. Alka Chavan**  
M.B.B.S., D.M.R.E.  
Reg. No. : 20060201251

(Reg. No. RGD/KPR/177)  
(Reg. No. : RGD/KJT/275)

**Dr. Gajanan Chavan**  
M.B.B.S., D.M.R.D.  
Reg. No. : 92147

# Endpoint findings

Clinically the presenting symptoms experienced by patient were comparatively less than before. Menstrual cycle was regularised within 3 months, last 2 months regular no noticeable incapacitating pain.

Urination pain frequency reduced than before. Only complaint is more urination, but no pain and burning like earlier.

Skin itching reduced but dryness is still there.

Patient has started being more active than before, no fatigue.

PEMF Magnet therapy is continued along with other medicines still for further recovery of patient. Esp. symptoms related to frequent urination and incontinence.

# BT & AT Comparison

Before Treatment: USG shows a single ovarian cyst, suspected to be endometrioma or haemorrhagic one.

After 6 months treatment : USG shows no ovarian cyst, Urinary bladder wall shows some inflammatory irregularities, suggesting cystitis.

# Conclusions

This is a single case study of the Treatment of a single large Ovarian cyst , where Ayurvedic medicines were combined with PEMF Magnet therapy, as an Adjuvant therapy.

It has led to faster recovery of the patient.

More such studies are needed for Adjuvant effect of PEMF Magnet therapy, leading to faster recovery of the patients towards well-being.

# Why PEMF as Adjuvant Therapy

Restoring the lost balance among Panch*Mahabhuta*-

- We use *Ayurvedic medicines and Panchkarma* procedures to control four of the five *Mahabhuta*.
- The main focus of *Chikitsa kriya is on-* to simulate, recreate, balance the *Pancha mahabhuta* in the body.
- The exceptional one, *Akash Mahabhut* can be simulated, cleared (*StrotoVishodhan*) with Anmol Pulsar V1 PEMF Magnet therapy device, up to a certain extent.
- Once all the *Panch Mahbuatas* are focused to be in Sam or Balance, we can get better, rapid and long lasting results.
- Ease of use by patient- It is very easy to apply Anmol Pulsar V1. (Kumar's Magnet)

*Thank you*